

Epistaxis

Objective

Understand the incidence/prevalence, clinical presentation, and the management of epistaxis

Definition

Epistaxis means 'nose bleed'.

Prevalence

~ 60% of the population in a lifetime

~ 6% require medical intervention

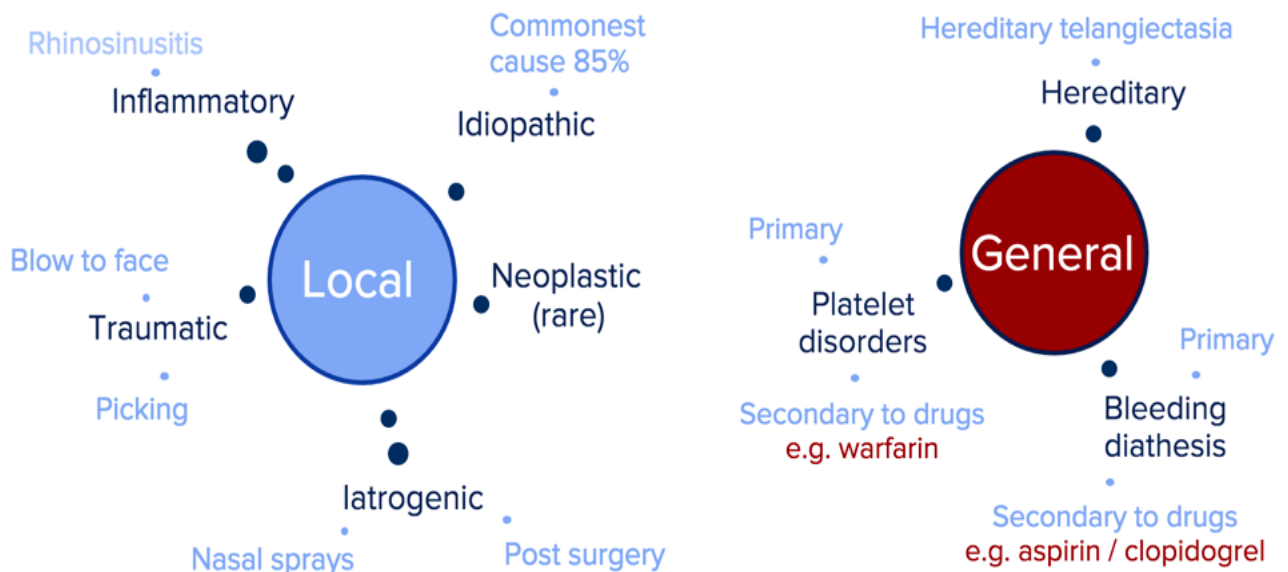
Mostly ages 2 -10 & 50 - 80

Potentially fatal!

Aetiology

The causes of epistaxis can be broadly split into two categories

1. Local
2. General (systemic)



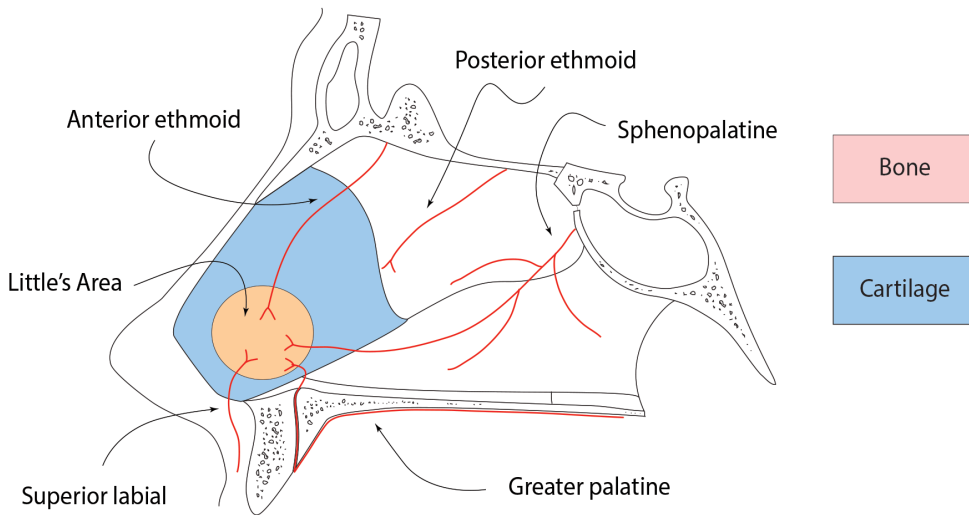
Note. Hypertension does not cause epistaxis, however it prolongs bleeding when established.

Anatomy of a nose bleed

Blood supply

The nasal cavity has a rich and complex blood supply that makes it ideally suited for its function of warming inspired air.

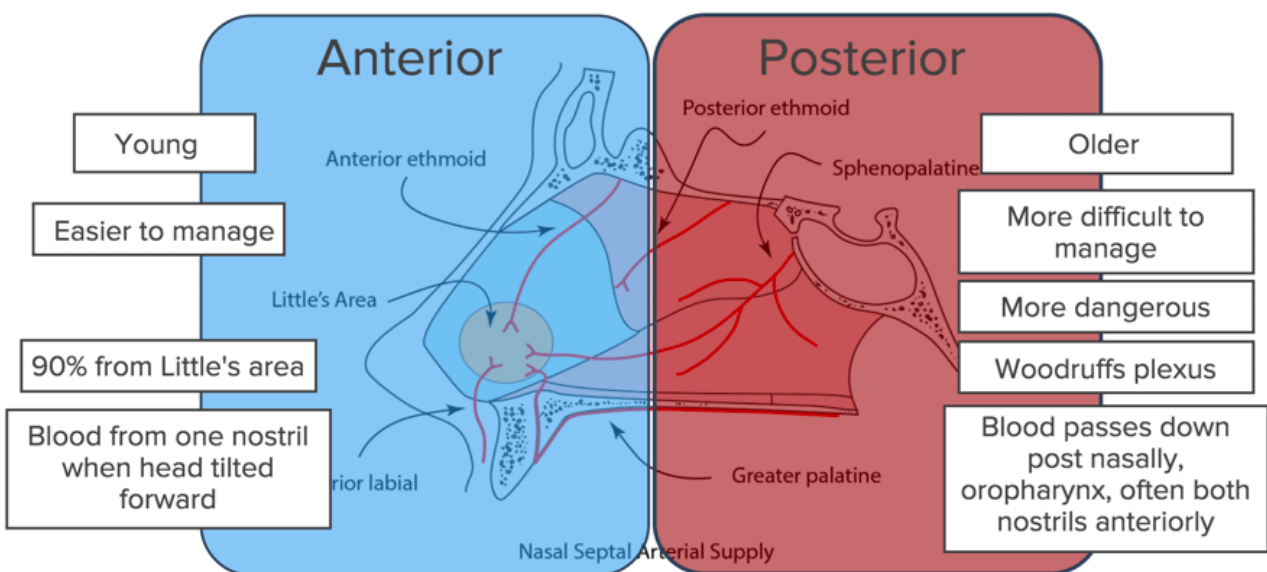
The diagram below shows the nasal septum is supplied by 5 main arteries. The vessels anastomose to form a network of vessels on the anterior nasal septum called Little's area (Kiesselbach plexus). This is the most common bleeding site seen in 90% of anterior bleeds.



Nasal Septal Arterial Supply

There is a second site of anastomosis seen on the posterior nasal septum called Woodruff's plexus.

Epistaxis can be broadly categorized into two main types depending on the location of the bleeding vessel. These types are summarized by the diagram below.



In reality the location of the epistaxis can be difficult to establish and some anterior bleeds can be very heavy and it may be difficult to achieve haemostasis.

Epistaxis Management

Management

The management of epistaxis should be tackled with a methodical, stepped approach. The algorithm below summarizes this approach nicely and is how we would proceed in the UK.

Please note as part of the assessment baseline bloods are taken. FBC for Hb, U&E, coagulation screen and group & save or cross-match if bleeding were severe.

Epistaxis management Algorithm

Step 1

Assessment of the patient with ATLS principles, **ABCD approach**, patient resuscitation

Step 2

Simple first aid
"15 minutes of uninterrupted pressure on soft part of nose with head tilted forward"

Step 3

Examination of the nasal cavity. Identify bleeding point

Step 4

Silver nitrate / electric cautery

Step 5

Haemostasis achieved ?

YES ✓

NO

Patient discharged with naseptin nasal cream 2/52.

Epistaxis advise sheet

Insertion of anterior nasal packing

Step 6

Haemostasis achieved ?

YES ✓

NO

Pack removed after 24 hours
Repeat from step 2

Posterior pack insertion
+/- theatre

Nasal cautery

Nasal cautery is the process of sealing the bleeding vessels and can be conducted in a number of ways. There are two main methods commonly used by most ENT departments:

1. Silver nitrate (cautery sticks)

A small plastic stick with silver nitrate on the end that reacts when in contact with the moist nasal mucosa.

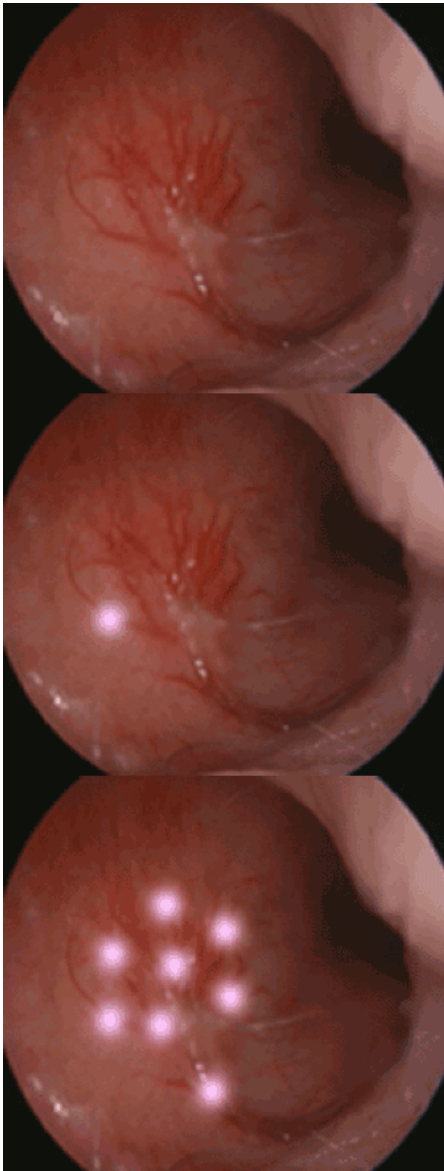


2. Electrocautery (specialist ENT department)

Usually conducted in an operating theatre.

Cautery should not be conducted bilaterally as this will damage the blood supply to the cartilaginous nasal septal resulting in a perforation.

The three images below illustrate cautery of an anterior epistaxis.



This is the left Little's area. A rich anastomosis is seen

Silver nitrate cautery is applied to the periphery of the anastomosis first. It leaves a small grey chemical burn over the vessel which denatures protein and causes occlusion of the blood vessel and eventual scarring.

Cautery progresses so that all the vessels are touched.

Generally, one starts with the smaller ones and work towards the largest.

Anterior nasal packing

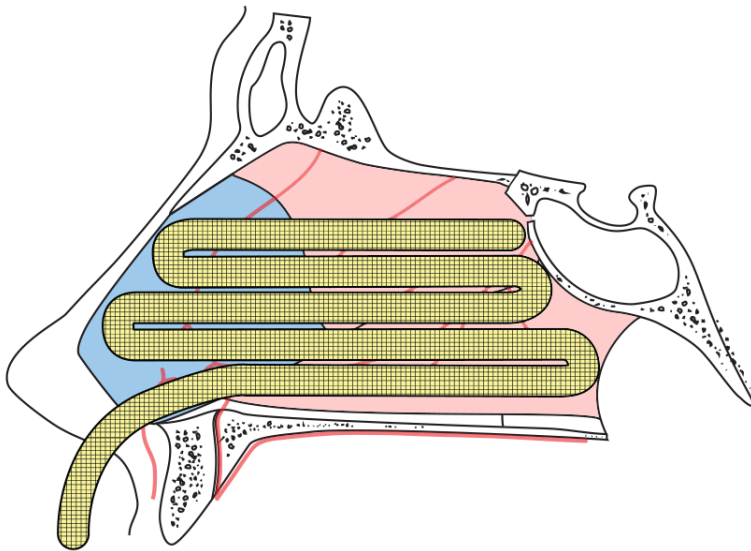
Nasal packing is placed when simple haemostasis measures fails. Packs come in a variety of different shapes and sizes. Simple ribbons coated in Vaseline or Bismuth and Iodoform mixtures are used with great success when alternative wafers and balloons are not available. This YouTube video demonstrates this: <https://www.youtube.com/watch?v=3w1VbQ7xTVs>

Packs work on the theory of creating a pressure tamponade on the bleeding vessels.

Placement method

Packs are always inserted parallel to the floor of the nose and pushed backwards towards the nasopharynx. If ribbon is being used then the free end is taped to the patient's cheek.

The pack is left in situ for 24 hours to allow clot formation. In persistent bleeding, a posterior pack can be inserted.



The ribbon is placed in layers, one on top of the other, until the nasal cavity is filled.

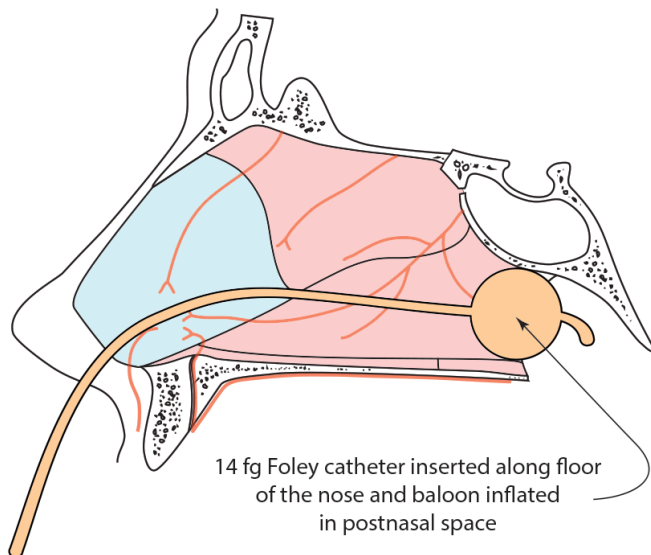
Clinical Note

If a pack is in for >24hrs then prophylactic antibiotics are given to prevent infection in the nose, sinuses or middle ear.

Posterior nasal packing

For posterior epistaxis, in which an anterior nasal pack has failed to achieve haemostasis, a posterior pack can be inserted to halt the bleed.

As for anterior nasal packing if haemostasis is not achieved with a single pack, a second pack can be inserted into the collateral nostril to tamponade the septum and completely pack the nasal cavity.

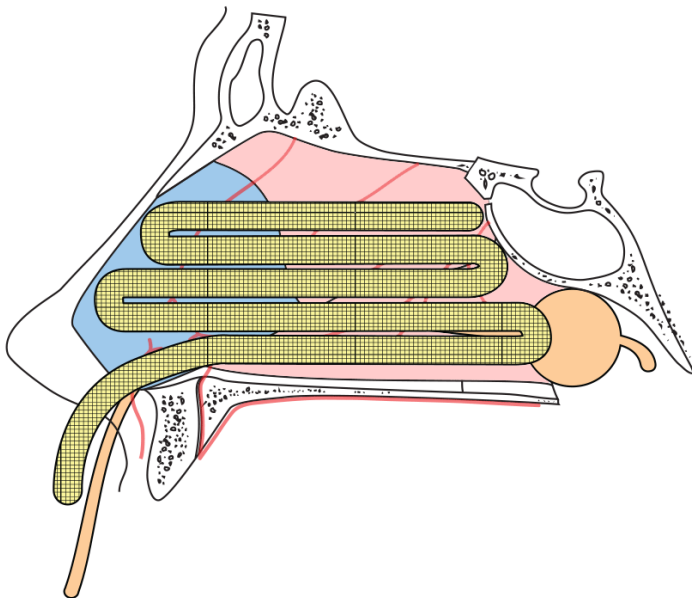


Placement method

A Size 14fg Foley catheter is inserted into the nostril and advanced until visualised in the oropharynx.

The balloon is inflated with 10ml of sterile water to occlude the choana.

The anterior nasal cavity is packed and a clamp holds the catheter in place. The clamp is regularly rotated and gauze is used to protect the skin of the nasal alar from pressure necrosis. The diagram below shows this.



Posterior packs are usually left for 24 hours

Clinical Note

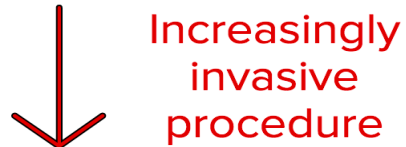Alar necrosis has a massive cosmetic impact by causing unsightly scarring.

Surgical management

Surgical management is a last resort for patients who have failed to achieve haemostasis with conservative management. As with all treatments a stepped approach is advised with many patients requiring simple measures in the controlled theatre environment. Other patients require higher risk procedures when all else has failed.

The list below summarizes this stepped approach with a patient moving onto the next more invasive procedure if haemostasis fails with the attempted method.

1. Examination under anaesthetic
2. Electrocautery
3. Vessel ligation (e.g. SPA)
4. Ligation of external carotid



There are patients who still have bleeding even after all of the above has been done. These may benefit from embolization.