Anatomy of the Ear

ENT·Education·Gambia
"Education through Innovation"

The ear consists of three parts: the outer ear, the middle ear and the inner ear. Each of these has a number of structures within it.

The Outer Ear

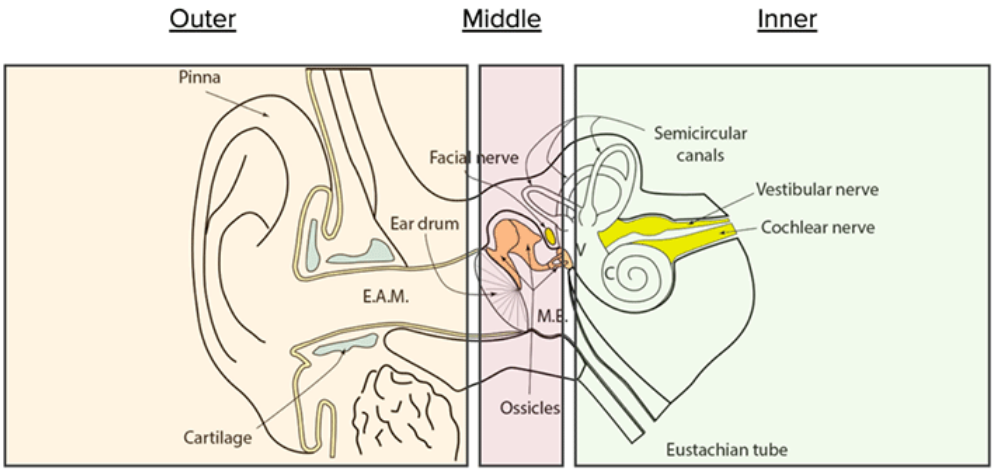

The outer ear is made up of the pinna and external ear canal. The canal is a sigmoid shaped skin lined tube, which has a cartilaginous (outer) and bony part (medial). The tympanic membrane demarcates the end of the outer ear and the beginning of the middle ear.

Normal ear drum anatomy

This is a normal left tympanic membrane. Take time to identify the normal anatomy of this structure.

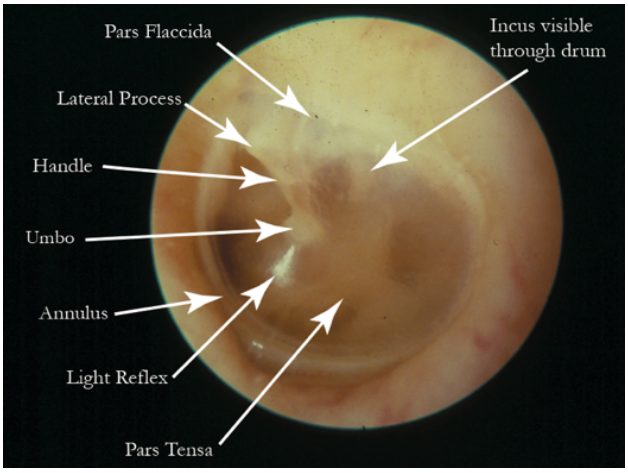

These are terms that are used frequently in the ENT clinic and in text books.

Annulus

The annulus is a thickened ring of collagen at the periphery of the pars tensa. It does not surround the pars flaccida. It sits in a bony groove in the tympanic bone. A cross section of the pars tensa finds the annulus to be a thickening of the middle fibrous layer of the tympanic membrane. A normal right tympanic membrane. Take time to identify the normal anatomy of this structure.

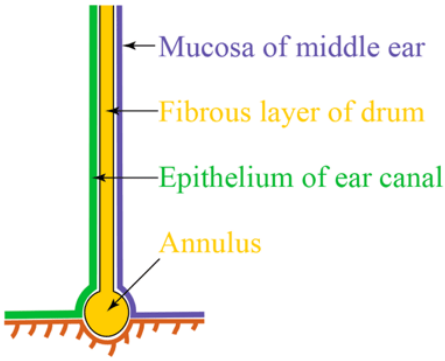

Attic

The attic is a term used to describe loosely the space in the middle ear that lies above the level of the lateral process of the malleus. Consequently, most of it cannot truly be seem from the outside unless it has been exposed by disease. In health the attic contains the head of the malleus and body of the incus together with their suspensory ligaments.

Handle (of the malleus)

The most lateral of the three ossicles is the malleus. It is attached to the fibrous layer of the tympanic membrane by it's handle. This is visible from the outside.

The handle is orientated backwards and downwards in health but in tympanic membrane retraction it appears more horizontal.

Lateral process (of malleus)

This is simply a short process from the malleus that tents up the tympanic membrane.

Light reflex

This is found in the anterior inferior quadrant of the tympanic membrane when the tympanic membrane is healthy. A diagram of the quadrants of the tympanic membrane is shown below. The reflex is light being reflected directly back to the observer.

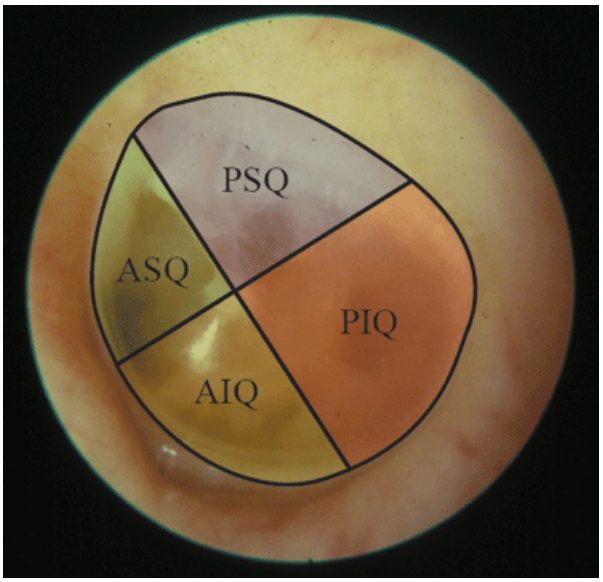

The four quadrants of the tympanic membrane:

1. PSQ posterior superior quadrant
2. ASQ anterior superior quadrant
3. PIQ posterior inferior quadrant
4. AIQ anterior inferior quadrant

Pars flaccida

This makes up the superior one fifth of the ear drum. It lies above the anterior and posterior malleolar folds and has no annulus. It is quite thin and floppy and is, therefore, prone to retraction when there is negative middle ear pressure.

Pars tensa

This makes up the majority of the tympanic membrane. It is a firm structure with an annulus. The malleus is attached to it. In general, it is strong but that part of it in the posterior superior quadrant is slightly weaker than the rest and retraction can start here.

Umbo

This is the region of the tympanic membrane at the lowest tip of the malleus. It is here that all of the cells that make up the outer layer of the tympanic membrane and the ear canal originate. They migrate outwards across the membrane then out along the ear canal. Once out of the ear canal they die and are shed.

The Middle Ear

The middle ear is a space within the temporal bone that contains the ossicles, facial nerve, corda tympani and air. It communicates with the nasopharynx via the Eustachian tube and with the mastoid air cells within the mastoid bone via the aditus.

It has three main regions and these are defined by their relationship with the eardrum. The area above the eardrum is called the epitympanum, below the eardrum the hypotympanum and level with the drum the mesotympanum. The diagram below illustrates this and shows the other important structures together with short notes.

- Epi - epitympanum, above level of drum
- Meso - mesotympanum, medial to drum
- Hypo - hypotympanum, below level of drum. It is small in this case but is often large and has 'stalagmites' of bone growing up from it.
- VII - Facial Nerve. Its presence here makes it vulnerable in ear diseases.
- ET - Eustachian Tube

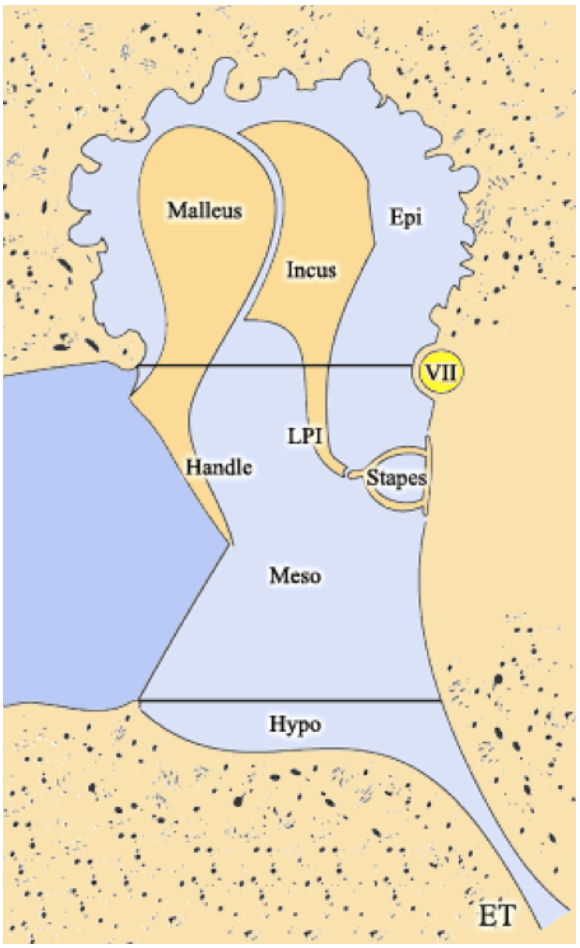

Malleus - notice that the majority of the malleus lies above the level of the drum in the epitympanum. It is only the handle of the malleus that is easily visible on otoscopy. This is the part attached to the fibrous layer of the ear drum

Incus - as with the malleus the body of the incus lies above the level of the drum and cannot be seen on otoscopy. One can often see the long process of the incus (LPI) through the drum

Stapes - this is the smallest bone in the body. Its head can sometimes be seen through the eardrum

Anatomic Relations

You should not get bogged down with the complex anatomy of the region but the following would be regarded as essential information. Most of the relationships on this list are common sense when you think about your own ear.

Superiorly

1. Meninges of middle cranial fossa
2. Temporal lobe of brain

Medially

1. Cochlea
2. Semicircular canals
3. Facial nerve

Inferiorly

1. Sternomastoid muscle
2. Jugular vein

Posteriorly

1. Mastoid
2. Meninges of posterior cranial fossa
3. Cerebellum
4. Sigmoid sinus

There are anterior relations as well but these are seldom affected. Any of these structures can be affected by diseases in the ear.

Physiology

So why do we have a middle ear? The easy answer is that it is there to amplify sound. And this is true, it does amplify it about twenty times.

However, there is another reason. To understand the reason consider what happens when you are in a swimming pool. Let us imagine that your friend is calling to you from the side of the pool but that you are under water. Do you hear him clearly? The answer is no but the question is, why not?

It is because most of the sound is reflected from the surface of the water and only a small portion causes vibration in the water. Thus he sounds very quiet.

Now think about the ear again. We are trying to hear sound waves that are in air but our organ of hearing (cochlea) is a fluid filled organ. Without a middle ear mechanism most of the sound vibrations would be reflected off the fluid surface of the inner ear. However, with a middle ear mechanism we are able to focus all of the sound energy, amplify it and 'funnel' it into the inner ear.

Without a middle ear mechanism, the world would be a lot quieter.

The Inner Ear

The inner ear is a complex three dimensional shape with semicircular canals, dilations called the utricle and saccule and a spiral portion known as the cochlea. All of these organs are housed inside a bony shell known as the bony labyrinth and this is within the temporal bone.

The cochlea is the site where sound is transformed into neural energy for hearing. The rest is concerned with balance.

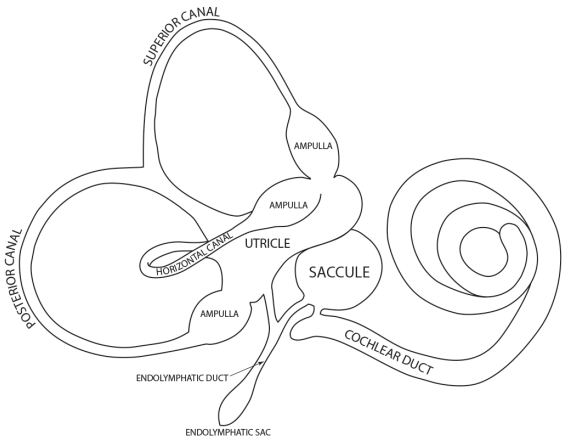

The Right Labyrinth

This diagram shows the membranous labyrinth and it is this that contains the neuroepithelia that detect motion and sound. It lies inside a bony shell – the bony labyrinth. The bony and membranous labyrinths are separated by a fluid filled space.

Despite the complexity of its shape it can be simplified as in the following diagram.

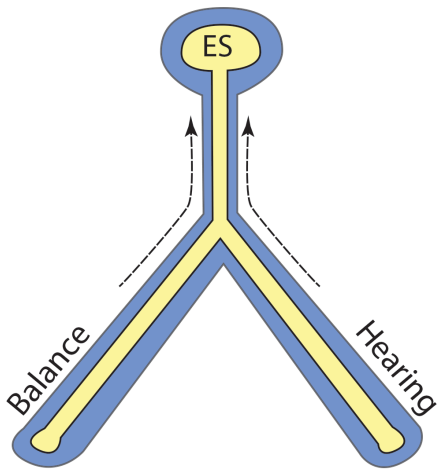

The yellow central portion in the diagram represents the membranous labyrinth. It contains endolymph and all of the neuroepithelia required for hearing and balance.

Surrounding this membranous labyrinth is a fluid filled space. This space separates the membranous labyrinth from the bony labyrinth. The space is filled with perilymph and can be considered to act in the same way as CSF - as a cushion for the delicate structures it protects.

The endolymph is produced by Dark cells within the membranous labyrinth. The dilated portion in this diagram represents the endolymphatic sac (ES). This is thought to regulate the volume and composition of the endolymph although how this is done is open to speculation.

If the composition or specific gravity of the endolymph is changed, as in Meniere's Syndrome or alcohol consumption, the function of the balance and hearing epithelia within it are affected.

Neural and Vascular Supply

The inner ear is supplied by the Superior Vestibular Nerve, the Inferior Vestibular Nerve and the Cochlear Nerve. All of these nerves travel from the inner ear towards the brain stem within the Internal Acoustic Meatus. Along with these in the IAM is the Facial Nerve and the vascular supply.

The nerve supply to the inner ear

In this diagram we visualise the inner ear. The cochlea is supplied by the cochlear nerve. The utricle, some of the saccule, the lateral semicircular canal and the superior semicircular canal are all supplied by the superior vestibular nerve. The posterior canal is supplied via the inferior vestibular nerve. This nerve also supplies part of the saccule. The cochlea is supplied by the cochlear nerve.

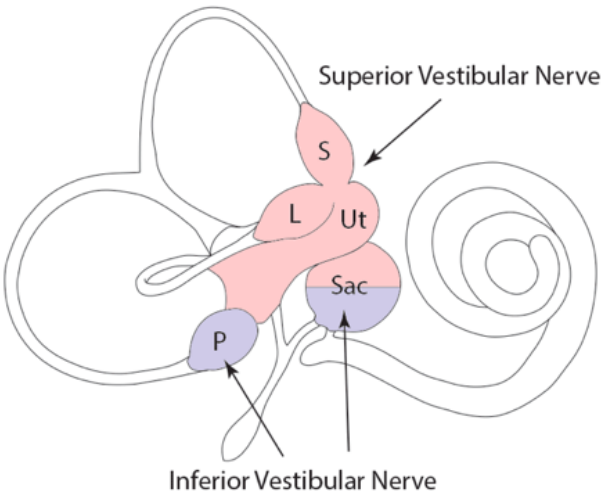

The blood supply to the inner ear

The diagram below outlines the blood supply for the inner ear. The anterior vestibular artery supplies the utricle, superior canal and the lateral canal. The posterior vestibular artery supplies the posterior canal. Both of these are branches of the common cochlear artery which ultimately is derived from the anterior inferior cerebellar artery.

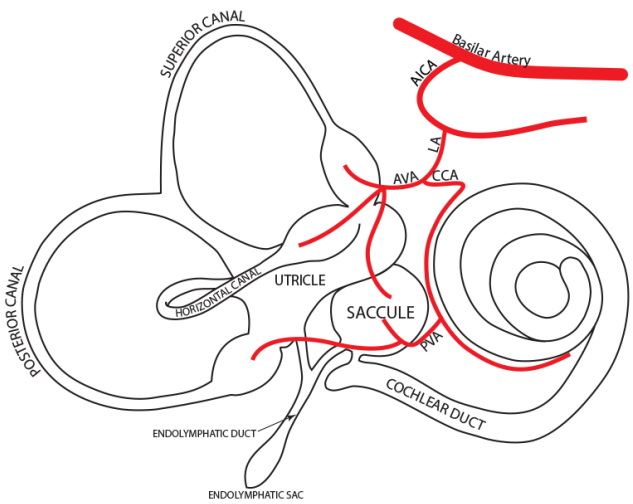

The Internal Auditory Meatus

The IAM is the bony conduit in the petrous temporal bone through which the vestibular, cochlear and facial nerves leave the posterior fossa. Note that there are two vestibular nerves on each side, a larger superior and a smaller inferior nerve.

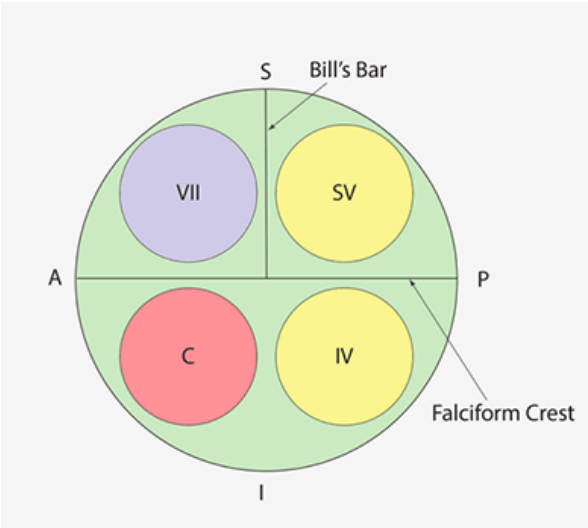

The Right Internal Acoustic Meatus

In the diagram imagine standing at the brainstem and looking outwards towards the Right ear.
S= superior, I= inferior, A= anterior, P= posterior.
VII is the Facial Nerve, C is the Cochlear Nerve,
SV is the Superior Vestibular Nerve, and
IV is the Inferior Vestibular Nerve.

The vertical line represents Bill's Bar while the horizontal line is the Crista Falciformis. The Nervus Intermedius travels with the Facial Nerve and is not shown.